



Diabetic Retinopathy Diagnosis Categorization Using Deep Learning

Rajitha K R

ME(CSE) Student Er. Perumal Manimekalai College of Engineering

Rajithanavi@gmail.com

Dr. N. Shunmuga karpagam

Associate Professor/CSE Er. Perumal Manimekalai College of Engineering

shunmugakarpagam@gmail.com

C.Santhosh Kumar

Assistant Professor Department of Computer Science and Engineering

Er.Perumal Manimekalai College of Engineering, Tamilnadu

cjsksag@gmail.co

Article

History

Received:
08July2023
Revised: 20
Sept 2023
Accepted:30
Sept 2023

CCLicense

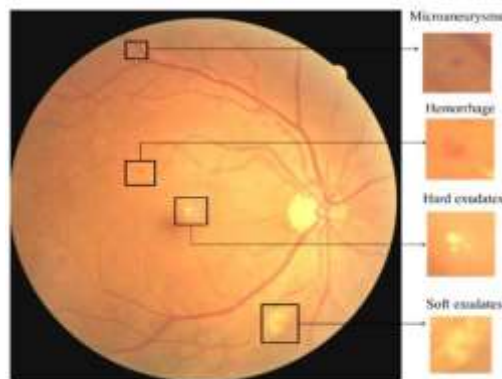
CC-BY-
NC-SA
4.0

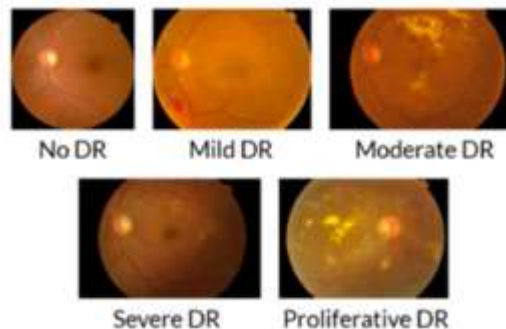
Abstract

Diabetic Retinopathy (DR) is an eye disease associated with chronic diabetes. DR is the leading cause of blindness among working aged adults around the world and estimated it may affect more than 93 million people. Progression to vision impairment can be slowed or controlled if DR is detected in time, however this can be difficult as the disease often shows few symptoms until it is too late to provide effective treatment. Currently, detecting DR is a time-consuming and manual process, which requires an ophthalmologist or trained clinician to examine and evaluate digital color fundus photographs of the retina, to identify DR by the presence of lesions associated with the vascular abnormalities caused by the disease. The automated method of DR screening will speed up the detection and decision-making process, which will help to control or manage DR progression. This paper presents an automated classification system, in which it analyzes fundus images with varying illumination and fields of view and generates a severity grade for diabetic retinopathy (DR) using machine learning models such as CNN, VGG-16 and VGG-19. This system achieves 80% sensitivity, 82% accuracy, 82% specificity, and 0.904 AUC for classifying images into 5 categories ranging from 0 to 4, where 0 is no DR and 4 is proliferative DR.

Introduction

Diabetic retinopathy (DR) is one of the most complicated issues of diabetic patients in which the retina becomes damaged and leads to blindness. It affects the blood vessels in the retina and due to leakage of fluid distort the vision completely. DR progress through mainly four stages; The earliest stage is Mild nonproliferative retinopathy, where only microaneurysms can occur. The second stage is Moderate nonproliferative retinopathy, where the blood vessels' lose their ability of blood transportation because of their distortion and swelling with the progress of this disease . The next stage is Severe non-proliferative retinopathy, which results in deprived blood supply to the retina due to the increased blockage of more blood vessels signaling the retina for the growing of fresh blood vessels. The final stage is Proliferative diabetic retinopathy, which is an advanced stage , where the growth features secreted by the retina activate proliferation of the new blood vessels, growing along the inside covering of retina in some vitreous gel, filling the eye. Each and every stage has its own characteristics and particular properties. But doctors possibly could not take some of them into account and thus make an incorrect diagnosis. So this leads to the idea of creation of an automatic solution for DR detection. DR can lead to a loss of vision if it is in an advanced stage. Worldwide, DR causes 2.6% of blindness. The possibility of DR presence increases for diabetes patients who suffer from the disease for a long period. Retina regular screening is essential for diabetes patients to diagnose and to treat DR at an early stage to avoid the risk of blindness. DR is detected by the appearance of different types of lesions on a retina image. These lesions are micro-aneurysms (MA), hemorrhages (HM), soft and hard exudates (EX). Microaneurysms (MA) is the earliest sign of DR that appears as small red round dots on the retina due to the weakness of the vessel's walls. The size is less than 125 μm and there are sharp margins. Michael et al. classified MA into six types. The types of MA were seen with AOSLO reflectance and Different types of DR lesions





The Diabetic Retinopathy stages

Existing System

Proliferative DR represents the latter stages of DR and represents an antigenic retinal response, in which angiogenesis is a physiological process in which new vessels form from pre-existing blood vessels. As a future direction, upcoming studies should focus on leveraging SSL methods to not only generalize but also be able to generate new fundus images based on the learned features using generative networks. Generative adversarial networks (GAN) and Variation auto-encoders (VAE) can be combined with existing networks to synthesize a whole range of enhanced fundus images that can be made available for training.

Proposed System

This paper reviews and analyzes state-of-the-art deep learning methods in supervised, self-supervised, and Vision Transformer setups, proposing retinal fundus image classification and detection. For instance, referable, non-referable, and proliferative classifications of Diabetic Retinopathy are reviewed and summarized. Moreover, the paper discusses the available retinal fundus datasets for Diabetic Retinopathy that are used for tasks such as detection, classification, and segmentation. The utilization of self-supervised vision transformers, such as DINO proposed by to encode better features when large-scale DR sets are provided. Transformers have shown a positive correlation between the number of trainable parameters and accuracy, hence they are immune to saturation with larger sets and varying data distributions. Emphasis has also been put towards effective image processing techniques as proposed to further enhance model performance. In computer aided diagnosis (CAD), features of exudates and hemorrhages are highly detectable. This allows fundus images to be clustered into proliferative and no proliferative cases, where mild and severe vessel abnormalities are distinguished from low level less critical lesions.

Literature Survey

[1] **AUTHOR:** Anas Bilal 1, Liucun Zhu 2,*, Anan Deng 1, Huihui Lu 1 and Ning Wu 1,*.

TITLE: AI-Based Automatic Detection and Classification of Diabetic Retinopathy Using U-Net and Deep Learning.

YEAR: 2022

Diabetes related retinal vascular disease is one of the world's most common leading causes of blindness and vision impairment. Diabetic Retinopathy automatic detection methods have traditionally been based on hand-crafted feature extraction from the retinal images and using a classifier to obtain the final classification. Early detection is essential in the treatment of diabetic retinopathy patients. This study used AI models to classify the fundus images' severity.

[2] AUTHOR: Wejdan L. Alyoubi 1,* Maysoon F. Abulkhair 1 and Wafaa M. Shalash 1,2

TITLE: Diabetic Retinopathy Fundus Image Classification and Lesions Localization System Using Deep Learning

YEAR: 2021

Diabetic retinopathy (DR) is a disease resulting from diabetes complications, causing non-reversible damage to retina blood vessels. DR is a leading cause of blindness if not detected early. The leaking blood and fluids appear as spots, called lesions, in the fundus retina image. The currently available DR treatments are limited to stopping or delaying the deterioration of sight, highlighting the importance of regular scanning using high-efficiency computer-based systems to diagnose cases early.

[3]AUTHOR:RUBINA SARKI , KHANDAKAR AHMED , (Senior Member, IEEE), HUA WANG , (Member, IEEE),AND YANCHUN ZHANG , (Member, IEEE)

TITLE: Automatic Detection of Diabetic Eye Disease Through Deep Learning Using Fundus Images: A Survey

YEAR: 2020

Diabetes Mellitus, or Diabetes, is a disease in which a person's body fails to respond to insulin released by their pancreas, or it does not produce sufficient insulin. People suffering from diabetes are at high risk of developing various eye diseases over time. There are two stages of DR: early DR and advanced DR. In early DR, new blood vessels do not developing (proliferating) and this is generally known as nonproliferative diabetic retinopathy (NPDR). As a result of advances in machine learning techniques, early detection of diabetic eye disease using an automated system brings substantial benefits over manual detection.

[4] AUTHOR: Parshva Vora and Sudhir Shrestha *

TITLE: Detecting Diabetic Retinopathy Using Embedded Computer Vision.

YEAR: 2020

People who have diabetic retinopathy may not have symptoms until the condition becomes severe, which may eventually lead to vision loss. Diabetic retinopathy (DR) is caused by damage to the blood vessels in the tissue at the back of the eye (retina) causing vision impairment and blindness. Uncontrolled blood sugar is a major risk factor. Since diabetic retinopathy lacks early symptoms, it is very difficult to detect the diseases at an early stage. In this paper, we present development efforts on an embedded vision algorithm that can classify healthy versus diabetic retinopathic images.

[5] AUTHOR: Abdelouahab Attia¹, Zahid Akhtar², Samir Akhrouf³, Sofiane Maza⁴

TITLE: A SURVEY ON MACHINE AND DEEPLARNING FOR DETECTION OF DIABETIC RETINOPATHY

YEAR: 2020

Diabetic Retinopathy (DR) is one of the main causes of visual loss worldwide. Early detection and diagnosis can prevent and save the vision of diabetic patients or at least the progression of DR can be slowed down. The main focus of this paper is to provide a summary of the numerous methods designed for discovering hemorrhages, microaneurysms and exudates are discussed for eventual recognition of non-proliferative diabetic retinopathy.

Conclusion And Future Scope

This project successfully detects diabetes by using deep learning on fundus images and it can be used as one of the methods to detect diabetes in the future. CNNs promise to leverage the large amounts of images that have been massaged for physician interpreted screening and learn from raw pixels. The high variance and low bias of these models could allow CNNs to diagnose a wider range of nondiabetic diseases as well. Visualizations of the features learned by CNNs reveal that the signals used for classification reside in a portion of the image clearly visible by the observer. Moderate and severe diabetic retinal images contain macroscopic features at a scale that current CNN architectures CNN for training accuracy as well as validation accuracy. For future work model can train with system, with more number of processed data for getting higher accuracy result Diabetic retinopathy remains a major cause of visual impairment and blindness, just as diabetic nephropathy is a major cause of renal failure, owing to the growing burden of type 2 diabetes. Over one-third of the world's 285 million people with diabetes are estimated to have diabetic retinopathy, and one-third of these (approximately 3.2 million) have vision-threatening retinopathy. Nowadays, image processing techniques with deep learning have

performed a vital role in computer-aided systems to diagnose abnormalities in diabetic retinopathy. There are some possible directions that may help to fully utilize the deep learning approaches in a more effective way. In the literature, it was noted that most research work has been performed with the use of convolutional neural network models to develop deep multi-layer frameworks for the diagnosis of diabetic retinopathy using digital retinal fundus images, but on the other hand, the analysis and explanation of retinal photographs need ophthalmologists, which is time-consuming and very expensive task. The risk of vision loss from diabetic retinopathy has fallen dramatically over the past 3 decades with improvements in diabetes and blood pressure treatments, and with advances in laser surgery and intraocular drug delivery. Nevertheless, diabetes remains to be a major cause of blindness. This paper summarizes the state of the art in diabetic retinopathy research and provides a perspective on opportunities for future investigations.

References

- [1] S. Dua, N. Kandiraju, H. Thompson, “Design and implementation of a unique blood vessel Detection Algorithm towards Early diagnosis of Diabetic Retinopathy”, 2005
- [2] H Jiang, K Yang, M Gao, D Zhang “An interpretable Ensemble Deep learning model for Diabetic Retinopathy disease classification”, 2019
- [3] M Gandhi, R Dhanasekaran “Diagnosis of Diabetic Retinopathy Using Morphological Process and SVM Classifier”, 2013
- [4] Shu-I Pao, Hong-Zin Lin, Ke-Hung Chein, Ming-Chen Tai, “Detection of Diabetic Retinopathy Using Bichannel Convolutional Neural Network”, 2020
- [5] Deepthi K Prasad, Vibha L, and Venugopal K R, “Early Detection of Diabetic Retinopathy from Digital Retinal Fundus images”, December 2015
- [6] Amol Prataprao Bhatkar , “Detection of Diabetic Retinopathy in Retinal images using MLP Classifier” 2015
- [7] Mahendran Gandhi, “Diagnosis of Diabetic Retinopathy Using Morphological Process and SVM Classifier”, 2013
- [8] Mayush Shelar, Sonali Gaitonde, Amudha Senthilkumar, Mradul Mundra and Anurag Sarang “Detection of Diabetic Retinopathy and its Classification from the Fundus images” 2021

[9] Shu-I pao, Hong-Zin Lin, Ke-Hung Chein, “Detection of Diabetic Retinopathy Using Bichannel Convolutional Neural Network”,2020

[10] Simy Mary Kurian,Sujitha Juliet Devaraj,Vinodh P Vijayan, “Brain Tumour Detection by Gamma DeNoised Wvelet Segmented Entropy Classifier”,2021