



The Effect of Ursolic Acid and Hyperinsulinemia on the Liver and Kidney Function of Alloxan-Induced Diabetic Male Rabbits

Jinan Hilal^{1*}, Bushra F. Hasan¹, Yasmeen J. Mohammed², Abdul Razzak N. Khudair¹

¹Department of Physiology, pharmacology and Biochemistry, College of Veterinary Medicine, University of Basrah, Basrah, Iraq. Email: jinan.hilal@uobasrah.edu.iq

bushra.hasan@uobasrah.edu.iq dr.abdulrazak79@gmail.com

²Department of Diseases and Poultry Diseases, College of Veterinary Medicine, University of Basrah, Basrah, Iraq. Email: Yasmeen.mohammed@uobasrah.edu.iq

*Corresponding author's E-mail: jinan.hilal@uobasrah.edu.iq

Article History	Abstract
Received: 28 August 2022 Revised: 11 March 2023 Accepted: 12 March 2023	<p>The study aimed to examine the effect of extracted and standard ursolic acid in addition to hyperinsulinemia compared to vitamin B complex on the liver and kidney function of alloxan-induced diabetic male rabbits. The liver and kidney functions were determined and analyzed by one-way of a NOVA at variance software at a P-Value of 0.05. The result showed a significant decrease in aspartate aminotransferase (AST), alanine aminotransferase (ALT), alkaline phosphatase (ALP), and uric acid values in the groups treated with standard and extraction ursolic acid (UA) compared to the diabetic group. The rabbit group that was treated with vitamin B complex recorded a significant decrease in the three liver enzymes, uric acid, and creatinine values than the diabetic group. In addition, the rabbit group that was treated with hyperinsulinemia recorded a significant increase in aspartate aminotransferase (AST) and creatinine values than the diabetic rabbit group. While the histological results in the groups treated with standard and extraction ursolic acid had a clear ameliorative effect in liver and kidney function tests better than hyperinsulinemia, also vitamin B complex caused some good effects.</p>
CC License CC-BY-NC-SA 4.0	Keywords: <i>Ursolic Acid, Hyperinsulinemia, Diabetics.</i>

1. Introduction

Diabetes is a chronic metabolic disorder regarded as one of the most health troubles all over the world²⁹. It causes a high formation of free radicals and less antioxidant potential⁴. This stress caused by diabetes can cause renal and hepatic tissue damage¹⁸. Researches on diabetes treatment are of interest: to get rid of its bad effects including less body activity and increased body weight²⁵. The expensive costs of antibiotics drugs lead patients to search for a replacement for these drugs by herbs such as ursolic acid which is found in green apple peels in high content and is safe and efficient as mentioned by several works^{11,25}. Ursolic acid is a triterpenoid material that can be extracted from several fruits such as apples¹³. New studies suggested that it has many ameliorative effects against a high number of pathogenic effects caused by many causative agents or diseases. It acts as an antioxidant¹⁵, minimizing cell death in the liver and kidneys,

decreasing atrophy and causing more levels of expression of AMP in muscular tissue.⁵ Furthermore, ursolic acid could be regarded as a drug for treating diabetes and liver diseases⁹, decreasing the atrophy of muscular tissue⁷.

Ursolic acid stops the formation of glomerular hypertrophy in streptozotocin-induced diabetic mice³³, and it can stop the formation of fibrous tissue in the interstitial tissue in renal tubules³⁰. Also, it can alleviate renal damage in type 2 diabetic mice by down-regulating proteins in the signaling pathway to inhibit extracellular matrix accumulation; renal inflammation; fibrosis, and oxidative stress¹⁶.

Diabetes is a large health problem since diabetic nephropathy stage renal disease, and causes of death among patients with diabetes type 2²⁴. The exact mechanism of the pathogenesis of diabetic nephropathy has not yet been elucidated and no clinical drug can effectively reverse the progression of diabetic nephropathy². Therefore, new treatments for diabetic nephropathy are urgently needed. Currently, published data or experiments have shown that ursolic acid decreases renal oxidative stress, inflammation and fibrosis or ameliorates renal damage in diabetic male rabbits. This study is designed to examine the effects of extracted and standard ursolic acid in addition to hyperinsulinemia compared to vitamin B complex in treating the bad effects on some biochemical and histological structures of alloxan-induced diabetic male rabbits.

2. Materials And Methods

2.1. Ursolic acid extraction and purification

Green apples were peeled and the peels were collected and dried with hot air, then they were made as powder by grinding mill till it becomes ready for extraction. The ursolic acid was extracted at the research lab of the College of Veterinary Medicine, Basrah University, (280gm) of ground green apple peels was extracted with (1000 ml) of hexane by the extraction system. Then the solvent was filtered and evaporated under vacuumed pressure to get the extracted material³¹. The suspension which resulted was strongly shaken and incubated in a boiling water bath for 5 minutes then cooled in an ice bath for 2 minutes then centrifuged at (14000 rpm) for 10 minutes, the supernatant was discarded and the precipitate was harvested and dialyzed again. Then extracted material was purified by High Potency Liquid Chromatography. After the extraction process had been completed, the compound was identified by the Gas Chromatography GC-MS technique. The ursolic acid structure was confirmed by spectroscopic methods and comparisons with data from the literature³². Then they extracted and identified ursolic acid again concentrated by dialysis.

2.2 Animals of the experimental

Sixty mature male local rabbits (*Lepus Cuniculus*) were bought from the Basrah animal market, their weights ranged between (1-1.5 Kg) and aged (6-8) months, and kept in steel cages in the animal house of the College of Veterinary Medicine, Basrah University. They left for two weeks before the experiment to adapt to the new environment of a normal light /dark cycle. They were fed green alfalfa and concentrated pellets with *adlibitum* water intake.

2.3 Experimental design

The experiment was accomplished over six weeks as follows: two weeks for the adaptation, while induction of diabetes mellitus took two weeks and two weeks for the treatments. Animals were randomly divided into six treatment groups (ten animals in each group). Diabetes mellitus was inducted in all six groups by intravenous injection of 90 mg/kg body weight of alloxan for one dose in the femoral vein¹⁷. The alloxan doses were dissolved in one normal saline and administered immediately after the anesthetization of the animals using ketamine and xylazine¹⁰. After alloxan administration, a 20% glucose solution in clean water was drenched for each animal *adlibitum* for two days to avoid hypoglycemia shock which may occur at first. Rabbits of fasting blood glucose higher than (200mg\dl) were considered diabetic after alloxan injection measured by a glucose meter³. All the induced diabetic rabbits had a level of blood glucose mean of (250mg/dl) ranging from (200-300 mg/dl), then each group of the six groups was treated as follows:

First group: It is regarded as a control group with diabetic mellitus induction and left without any treatment. Second group: After diabetes induction animals were administered extracted ursolic acid daily for two weeks (50mg/kg) of ursolic acid dissolved in a quantity of ethanol and diluted in (1ml) physiological saline orally¹⁴. Third group: After diabetes induction animals were administered the same dose of standard ursolic acid orally in the same way as group two. Fourth group: Diabetes animals were injected with (1-2 IU/Kg) insulin subcutaneously daily for two weeks and regarded as hyperinsulinemia animals. Fifth group: Diabetes animals were treated daily for two weeks with a combination of the same above dose of extracted ursolic acid orally and injected insulin subcutaneously. Sixth group: Diabetes-induced rabbits were injected intramuscularly with (2mg/kg) vitamin B complex daily for two weeks¹⁴.

2.4. Collection samples

At the end of the two weeks treatment period blood samples were down from each animal of all groups by heart puncture by disposable (5ml) syringe transferred to EDTA container test tubes, then all blood samples were centrifuged and sera were harvested and kept in Eppendorf tube and freezer at -20°C until biochemical and lysis. Then all animals were authenticated and livers and kidneys were isolated and kept at 10% formalin solution for fixation. After that histological preparation for liver and kidney samples was performed and slides of 5-micron thickness were prepared and stained with hematoxylin and eosin then examined under microscope light at 40X magnification and photos of those slides were obtained by a special photographic microscope. Serum was analyzed for liver function test measurements such as aspartate aminotransferase (AST), alanine aminotransferase (ALT) and alkaline phosphatase (ALP), and kidney function tests such as uric acid and creatinine.

2.5 Statistical Analysis

Data obtained were presented as mean±SD. Significant differences among experimental groups were achieved by applying one-way ANOVA according to Abo-Allam¹.

3. Result And Discussion

In several countries, medicinal herbs are used to treat diabetes because they are regarded as safe and not toxic and have no side effects than chemical drugs. In our study, ursolic acid which is extracted from green apple peels showed effective hypoglycemic action on diabetic rabbits. Liver and kidney functions may also be affected by the change in insulin level, which had quick uptake of stored glycogen and usage of glucose, especially in the liver. In diabetes, the activity of glycogen synthase and hexokinase is diminished due to insulin deficiency. Glucose cannot be transformed into glycogen and glycogenesis is subsequently decreased. The concentration of glucose in the blood is hence increased²⁰. In another study done by Bolkent et al.⁸ in which the pancreas of diabetic rats was examined under a microscope, it was found that extracted ursolic acid increased insulin synthesis and release. Accordingly, blood glucose levels were reduced.

Induced diabetes rabbits in this study recorded significant variations in serum AST (28.76 IU/L) and ALP (17.560 IU/L) values. The ALT in diabetic rabbits of the current study is (59.246 IU/L) which is higher than the other diabetic-treated groups as shown in Table 1. These results are similar to those revealed by Ozean and Selcuk¹⁹. The decreased AST and ALP of diabetic rabbits in this study is unlike those of diabetic human found by Salman et al.,²³ who found a significant elevation of those two enzymes; except ALT which is significantly increased in rabbits resembling those of human being found by Salman et al.²³. These differences in reduction and elevation of these enzymes may be due to the short period of diabetic rabbits which is a longer period in human heads to clear significant effects resulting from the pronounced effects of diabetes on liver histology because in diabetes synthesis of protein is stopped and protein breakdown increases. Hepatocytes undergo destruction and their membranes decrease their permeability. It resulted in an increased passage of liver enzymes into the blood and increase activity¹⁷. The elevation of activity of AST and ALT and ALP which are synthesized in the liver and secreted in the bile is a feature of liver secretion dysfunction⁷.

Insulin affects fat in addition to the metabolism of protein and carbohydrates as well, so the decrease or increase of AST, ALT and ALP activity in ursolic acid treated group and B complex treated groups show parallel to the action of insulin on the metabolism of fat, but in case of hyperinsulinemia treatment, it caused a significant increase in AST only and a significant decrease in both ALT and ALP. Alloxan is always used in diabetic induction in laboratory animals, it destructs beta cell of the pancreas utilizing free radicals formed

from oxygen reduction which cause damage to hepatic cells leading to cause hyperglycemia which produce ROS, which causes oxidative stress²⁶. Results of AST in this study agreed with that found by Ismail et al¹²., which found no significant difference in AST of diabetic rabbits although it decreased in diabetic compared to normal. Ismail et al.,¹² declared that AST levels in diabetic rabbits are mainly in conflict³² and found decreased AST in diabetic compared to nondiabetic rabbits. The rabbit group that was treated with vitamin B complex significantly decrease the three liver enzymes than diabetic rabbits without treatment this may be due to the regenerative effect of the B complex vitamin on the hepatic tissue as it is clear from the histologic section Figure-6.

Table 1: Effect of uroslic acid, hyperinsulinemia and vitamin B complex on liver function tests (AST, ALT and ALP) of alloxan-induced diabetic male rabbit

Groups	AST IU\L	ALT IU\L	ALP IU\L
Control(Diabetes only)	28.760±2.405 b	59.246±1.552 a	17.560±10541 a
Diabetic+ Extracted(UA)	24.8±1.303 d	20.8±1.302 c	6.241±0.017 c
Diabetic + Standard (UA)	24.8±1.303 d	25.8±1.310 b	6.652±0.002 c
Diabetic + hyperinsulinemia	45.120±0.471 a	20.180±0.130 c	1.580±0.130 d
Diabetic+Extracted(UA)+ hyperinsulinemia	26.8±1.301 c	16.8± 1.311 d	9.743±0.003 b
Diabetic+ Vitamin B complex	21.4± 1.816 e	22.8±1.300 b	6.282±0.002 c

Means bearing different letters differ significantly at 5% level ($p < 0.05$).

In the current study, we observed a clear change in diabetic rabbits that caused several histopathological changes as reported under the micrograph of Figures-1,2,3,4,5 and 6. due to the different treatments, those changes coincided with the results of the biochemical function reported in Table 1. Hepatic changes in diabetic rabbits are represented by clear fusion of hepatocytes with enlargement of their nuclei and absence of sinusoids with clear blood, and engorgement of the central vein. There are some lipid accumulated in hepatocyte cytoplasm which appears as vacuoles (fatty liver degeneration due to histological changes as reported by Wang et al.²⁸

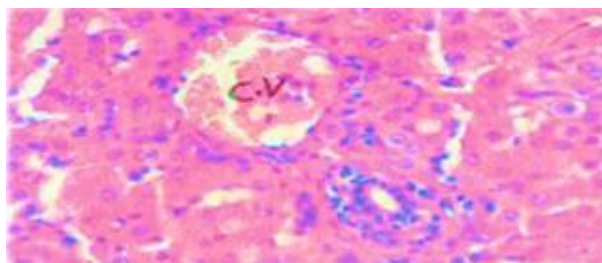


Figure -1: Micrograph of a section of liver of control group (diabetic only) shows clear fusion of hepatocyte with enlargement of their nuclei and absence of sinusoids with clear blood engorgement of central vein (C.V). (H & E stain 40x).

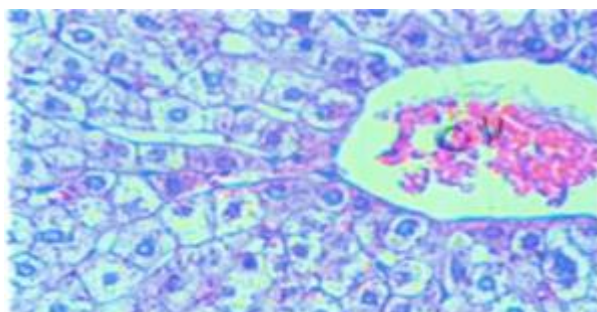


Figure- 2: Micrograph of section of liver of diabetic male rabbit treated with extracted ursolic acid shows clear arrangement of hepatocyte with clear radiated architecture clear hepatic nuclei. Absent of sinusoids, still there is blood engorgement of the central vein (C.V). (H & E stain 40x).

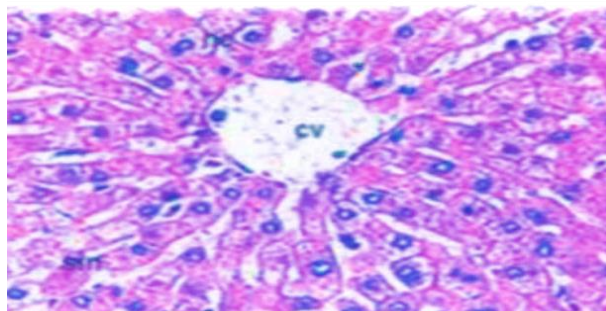


Figure -3: Micrograph of section of liver of Diabetic male rabbit treated with standard ursolic acid shows clear normal hepatocytes arranged in clear radiation architecture. Normal sinusoidal spaces, normal central vein (no blood engorgement). (H & E stain 40x).

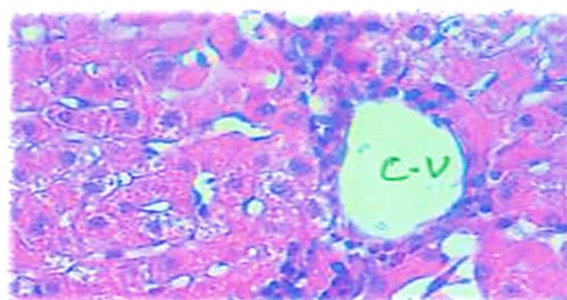


Figure -4: Micrograph of a section of liver of diabetic male rabbit treated with hyperinsulinemia shows, a clear empty central vein but there are abnormal arrangement of hepatic cells (distorted) absence of radiated architecture enlarged hepatic nuclei with flattening of hepatic cells.(H & E stain 40x).

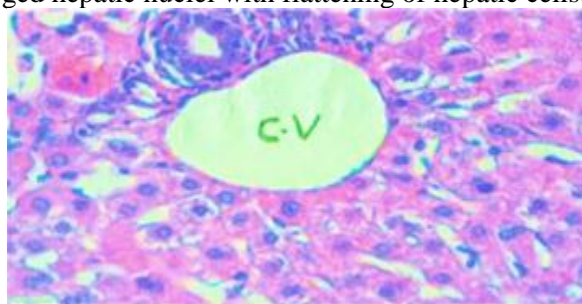


Figure -5: Micrograph of a section of a diabetic male rabbit treated with extracted ursolic acid and hyperinsulinemia shows some better radiation arrangement of hepatic cells still large nuclei, there can normal sinusoids, no blood engorgement in the centrally.(H & E stain 40x).

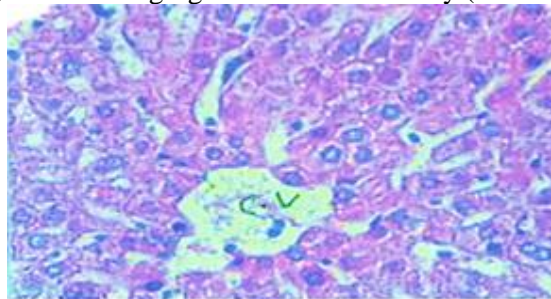


Figure- 6: Micrograph of a section of the liver of a diabetic male rabbit treated with vitamin B complex shows better arranged normal hepatic cells, normal sinusoidal spaces, clear empty central vein .(H & E stain 40x).

Induced diabetes in male rabbits of this study caused a significant increase in uric acid in the other group, as shown in Table 2, which is (3.640 mg/dl). However, nearly diabetes has no effect on creatinine which is (0.960 mg/dl). These results are similar to those reported by Ozean and Selcuk¹⁹. While Wang et al.,²⁸ found higher creatinine in diabetic rabbits, this study reported no increase. This difference may be attributed to the differences in rabbits strain used in the two studies. Also, Ozsoy-Sacan et al.,²⁰ found increased uric acid in diabetic rats (same trends as our study). The decrease in uric acid by administering ursolic acid either extracted or standard in this study comes in coincident with what is found by Pai et al.²¹ concerning the decrease of uric acid elevated by gentamycin treatment. Their results indicated that ursolic acid caused reno-protective effects from induced damage, but ursolic acid in this study caused a significant increase in creatinine which is not found in other studies. Hyperinsulinemia caused a significant increase in both uric and creatinine, and it may be ascribed to hypoglycemia resulting from a high dose of insulin.

Nonetheless, when ursolic acid is given together with hyperinsulinemia uric acid and creatinine were significantly ($p < 0.05$) decreased than in hyperinsulinemia alone and lower than that of ursolic acid alone. This may occur due to the synergistic effect between both ursolic acid and hyperinsulinemia. It is also clear that vitamin B complex significantly decreases both uric acid and creatinine this may be due to the ameliorative effect of the vitamin on the damaged renal tissue caused by diabetic induction as it is clear in kidney histologic section treated with vitamin B complex group.

Table 2: Effect of ursolic acid, hyperinsulinemia and vitamin B complex on kidney functions (uric acid and serum creatinine) of alloxan-induced diabetic male rabbits.

Groups	Uric acid mg\dl	Creatinine mg\dl
Control(Diabetes only)	3.640 ± 0.826 a	0.960 ± 0.336 d
Diabetic+ Extracted (UA)	0.890 ± 0.001 c	1.122 ± 0.002 b
Diabetic + Standard (UA)	0.053 ± 0.001 d	1.872 ± 0.001 b
Diabetic + hyperinsulinemia	2.680 ± 0.130 b	4.980 ± 0.130 a
Diabetic+Extracted (UA)+hyperinsulinemia	0.889 ± 0.002 c	1.072 ± 0.001 c
Diabetic+ Vitamin B complex	0.134 ± 0.004 d	0.872 ± 0.002 d

Means bearing different letters differ significantly at 5% level ($p < 0.05$).

Histological results of the current study revealed that induced diabetes in male rabbits caused clear changes in kidney tissue including changes in glomeruli and renal tubules and treatment with ursolic acid either extracted or standard and as well as accompanied with hyperinsulinemia and treatment with vitamin B complex revealed very good ameliorative effects as it is clear in Figures - 7, 8, 9,10, 11 and 12. These results were also confirmed by the results of many researchers such as Ma et al.¹⁶ who found that ursolic acid treatment decreases kidney tissue change in mice.

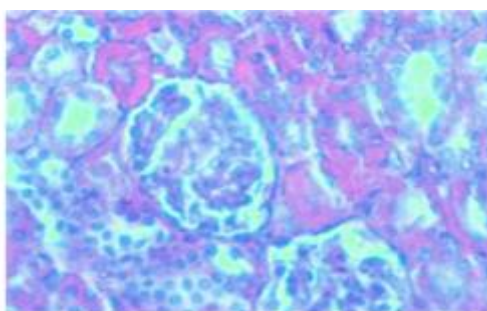


Figure -7: Micrograph of a section of the kidney of a diabetic male rabbit(control) shows an absence of walls of cuboidal lining cells the renal tubules with enlarged nuclei, and there are numerous free nuclei outside the cells. Some homogenization of renal cells (fusion of cells) fragmented contents of glomeruli.(H & E stain 40x).

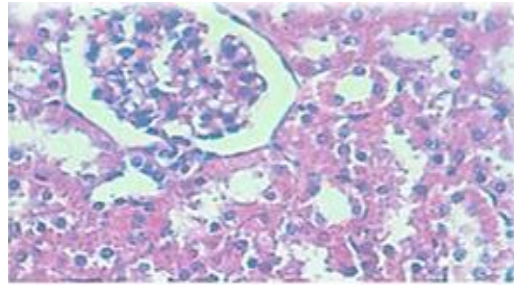


Figure- 8: Micrograph of the kidney of a diabetic male rabbit treated with extracted ursolic acid shows the better conformation of several renal tubules with better arrangement of cuboidal cell lining of renal tubules, better conformation of the glomerulus. (H & E stain 40x).

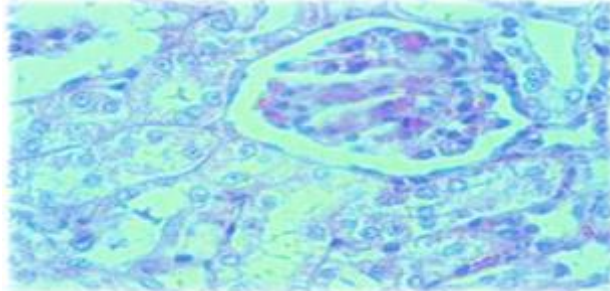


Figure -9: Micrograph of the kidney of a section of a diabetic male rabbit treated with standard ursolic acid shows very clear renal tubules lined by clear cuboidal cells with clear nuclei, normal glomerular content of bowman's capsule. (H & E stain 40x).

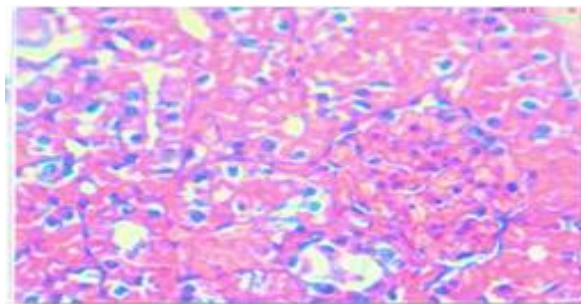


Figure -10: Micrograph of a section of the kidney of a diabetic male rabbit treated with hyperinsulinemia shows dense compact renal convoluted tubules with some normal cuboidal cell lining with large dense nuclei still distorted glomerulus with renal cells content. (H & E stain 40x).

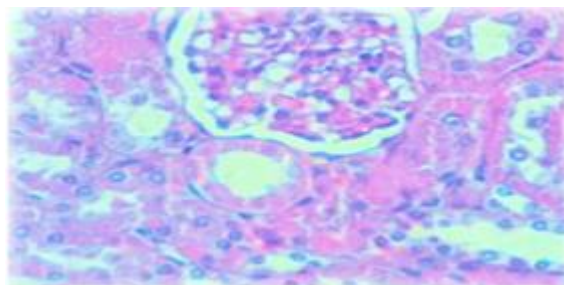


Figure- 11: Micrograph of kidney section of a diabetic male rabbit treated with extracted ursolic acid and hyperinsulinemia shows clear renal tubules lined with large clear cuboidal cells with large nuclei and good content of the glomerulus with some vacuoles. (H & E stain 40x).

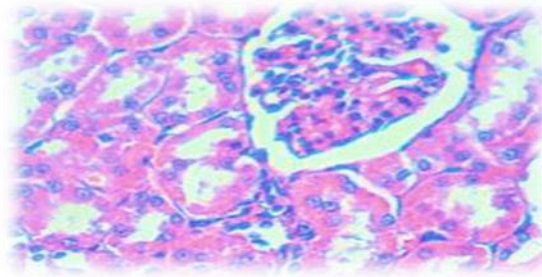


Figure -12: Micrograph of the kidney section of a diabetic male rabbit treated with vitamin B complex. Shows very good renal convoluted tubules formation with well lining cuboidal cells surrounding clear tubal spaces and good glomerular. (H & E stain 40x).

4. Conclusion

In this study, a significant decrease in aspartate aminotransferase (AST), alanine aminotransferase (ALT), alkaline phosphatase (ALP), and uric acid values in the group treated with standard and extraction ursolic acid (UA) compared to the diabetic group. The rabbit group that was treated with vitamin B complex recorded a significant decrease in the three liver enzymes, uric acid, and creatinine values than the diabetic group.

Acknowledgments

The authors would like to thank the College of Veterinary Medicine, University of Basrah, Iraq

Conflict of Interest

The authors have no conflict of interest.

Funding:

None.

References

- Abo-Allam, R. M. 2003. Data Statistical Analysis Using SPSS Program. 1st ed. Cairo Publication for Universities.
- Afkarian, M., C.M. Sachs, B. Kestenbaum, I. B. Hirsch, R. K. Tuttle, J. Himmelfarb, and H.I. de Boer, I. H., 2013. Kidney disease and increased mortality risk in type 2 diabetes. *Journal of the American Society of Nephrology*, 24:302-208. <https://doi.org/10.1681/asn.2012070718>
- Alam, S. S., A.H. Khan, A.G. Sirhindi and S. Khan, 2005. Alloxan induced diabetes in rabbits. *Pakistan Journal of Pharmacology*, 22(2):41-45.
- Bacanli, M., S. Aydin, H.G. Anlar, T. Çal, U. Ündeğer Bucurgat, N. Ari, A.A. Başaran and N. Başaran, 2018. Protective effects of ursolic acid in the kidneys of diabetic rats. *Turkish Journal of Pharmaceutical Sciences*, 15(2): 166–170. <https://doi.org/10.4274/tjps.49469>
- Bakhtiari, N., S. Hosseinkhani, M. Soleimani, R. Hemmati, A. Noori-Zadeh, M. Javan and A. Tashakor, 2016. Short-term ursolic acid promotes skeletal muscle rejuvenation through enhancing of SIRT1 expression and satellite cells proliferation. *Biomedicine and Pharmacotherapy*, 78: 185–196. <https://doi.org/10.1016/j.biopha.2016.01.010>
- Baraona, E.P., M. Pikkarainen and F. Salaspuro, 1980. Acute effects of ethanol on hepatic protein synthesis and secretion in the rat. *Gastroenterol*, 79: 104. [https://doi.org/10.1016/0016-5085\(80\)90082-7](https://doi.org/10.1016/0016-5085(80)90082-7)
- Bolkent, S., R. Yanardağ, A. Tabakoğlu-Oğuz and O. Ozsoy-Saçan, 2000. Effects of chard (Beta

- vulgaris L. var. Cicla) extract on pancreatic B cells in streptozotocin-diabetic rats : A morphological and biochemical study. *Journal of Ethno Pharmacology*, 73(1-2): 251–259. [https://doi.org/10.1016/s0378-8741\(00\)00328-7](https://doi.org/10.1016/s0378-8741(00)00328-7)
- Diarra, M., H. El Ouahabi, H. Bouxid, S. Boujraf, Y. Khabbal and F. Ajdi. 2016. Medicinal plants in type 2 diabetes: therapeutic and economical aspects. *International Journal of Preventive Medicine*.7:56. <https://doi.org/10.4103/2008-7802.178370>
- Eesa, M. J., R. A. Omar and H.H. Mohammad Nazhat, 2012. Evaluation of general anaesthesia by using Propionylpromazine, Xylazine and Ketamine in rabbits. *Iraqi Journal of Veterinary Medicine*, 34(1): 208–217. https://doi.org/10.30539/iraqijvm.v34i1.68_1
- Ezuruike, U. F. and J.M. Prieto, 2014. The use of plants in the traditional management of diabetes in Nigeria: Pharmacological and toxicological considerations. *Journal of Ethno Pharmacology*, 155(2): 857–924. <https://doi.org/10.1016/j.jep.2014.05.055>
- Ismail, C., Y. Esref and O. Fehm , 2002. Effect of experimental diabetes mellitus on plasma lactate dehydrogenase and glutamic oxaloacetic transaminase levels in rabbits. *Turkish Journal of Biology*, 26(3):151-154. <https://doi.org/10.1016/j.medici.2018.02.001>
- Jäger, S., H. Trojan, T. Kopp, M. N. Laszczyk and A. Scheffler. 2009. Pentacyclic triterpene distribution in various plants - rich sources for a new group of multi-potent plant extracts. *Molecules (Basel,Switzerland)*,14(6): 2016-2031. <https://doi.org/10.3390/molecules14062016>
- Kazmi, I., M. Afzal, S. Rahman, M. Iqbal, F. Imam and F. Anwar, 2013. Anti-obesity potential of ursolic acid stearyl glucoside by inhibiting pancreatic lipase. *European Journal of Pharmacology*, 709(1-3): 28–36. <https://doi.org/10.1016/j.ejphar.2013.02.032>
- Liobikas, J., D. Majiene, S. Trumbeckaite, L. Kursvietiene, R. Masteikova, D. M. Kopustinskiene and J. Bernatoniene, 2011. Uncoupling and antioxidant effects of ursolic acid in isolated rat heart mitochondria. *Journal of Natural Products*,74(7): 1640-1644. <http://dx.doi.org/10.1021/np200060p>
- Ma,T. K., L. Xu, L. X. Lu, L. X. X. Cao, X. Li, L. L. Li, X. Wang and Q. L. Fan, 2019 . Ursolic metab acid treatment alleviates diabetic kidney injury by regulating the ARAP1/AT1R signaling pathway. *Diabetes, Metabolic Syndrome and Obesity*, 9(12): 2597-2608. <https://doi.org/10.2147/dms.o.s222323>
- Mohamed , J., N. A. Nafizah, A. Zariyantey and B. S. Budin,2016. Mechanisms of diabetes-induced liver damage: The role of oxidative stress and inflammation. *Sultan Qaboos University Medical Journal*, 16(2): e132. <https://doi.org/10.18295/squmj.2016.16.02.002>
- Nair, M. 200. Diabetes mellitus, part 1: Physiology and complications. *British Journal of Nursing*, 16(3):184–188. <https://doi.org/10.12968/bjon.2007.16.3.22974>.
- Ozean O. and P. Selcuk, 2019. Normal values of biochemical parameters in serum of new zeland white rabbits. *Turk Hij Den Biyol Derg*, 76(2): 157-162. <https://doi.org/10.5505/TurkHijyen.2018.53254>
- Ozsoy-Sacan, O., O. Karabulut-Bulan, S. Bolkent, R. Yanardag and Y. Ozgey,2004. Effects of Chard (Beta vulgaris L. var cicla) on the Liver of the Diabetic Rats: A Morphological and Biochemical Study. *Bioscience, Biotechnology and Biochemistry*, 68(8-1) : 1640–1648. <https://doi.org/10.1271/bbb.68.1640>
- Pai, P.G., S. Chamari Nawarathna, A. Kulkarni, U. Habeeba, C.S. ReddyTeerthanath and J.P. Shenoy, 2012. Nephroprotective effect of ursolic acid in a murine model of gentamicin-induced renal damage. *ISRN Pharmacology*, 2012, 410902 <https://doi.org/10.5402/2012/410902>
- Rui, D., G. Angela, M. Durate, F. Carmen, N. Carlos, S. Carlos and S. Arnando, 2014. Bioactive

- triterpenic acids: From agroforestry biomass residues to promising therapeutic tools. *Mini-Reviews in Organic Chemistry*, 11(3): 382-399. <http://dx.doi.org/10.2174/1570193X113106660001>
- Salman, M. I., R.M. Rashied and H.S. Hamad, 2020. Study of liver function teste in diabetes type-2 patients in Ramadi city, Iraq. *Annals of Tropical Medicine and Public Health*, 23(18): 231824. <https://doi.org/10.36295/ASRO.2020.231824>
- Satirapoj, B. and S.G. Adler, 2014 . Comprehensive approach to diabetic nephropathy. *Kidney Research And Clinical Practice*, 33(3): 121–131.. <https://doi.org/10.1016/j.krcp.2014.08.001>.
- Shaw, J. E., R. A. Sicree and P. Z. Zimmet. 2010. Global estimates of the prevalence of diabetes for 2010 and 2030. *Diabetes Research and Clinical Practice*. 87: 4-14. <https://doi.org/10.1016/j.diabres.2009.10.007>
- Szkudelski, T., 2001. The mechanism of alloxan and streptozotocin action in β -cells of the rat pancreas. *Physiological Research*, 50: 536-546.
- Vieira, E. M., C. S. Ueno, V. N. Valva, M. D. Goulart, T. Nogueira and M. F. Gomes, 2008. Bone regeneration in cranioplasty and clinical complications in rabbits with alloxan-induced diabetes. *Brazilian Oral Research*, 22(2):184–191. <https://doi.org/10.1590/s1806-83242008000200015>
- Wang, J., R. Wan, Y. Mo, Q. Zhang, L.C. Sherwood and S. Chien, 2010. Creating a long-term diabetic rabbit model. *Experimental Diabetes Research*, 2010, 289614. <https://doi.org/10.1155/2010/289614>
- Wild, S., G. Roglic, A. Green, R. Sicree and H. King, 2004. Global prevalence of diabetes: Estimates for the year 2000 and projection for 2030. *Diabetes Care*, 27: 1047-1053. <https://doi.org/10.2337/diacare.27.5.1047>
- Xu, C. G., X. L. Zhu, W. Wang and X. J. Zhou, 2019. Ursolic acid inhibits epithelial-mesenchymal transition in vitro and in vivo. *Pharmaceutical Biology*, 57(1):169-175. <https://doi.org/10.1080/13880209.2019.1577464>
- Yamaguchi, H., T. Noshita, Y. Kidachi, H. Umetsu, M. Hayashi, K. Komiyama, S. Funayama and K. Ryoyama . 2008. Isolation of ursolic acid from apple peels and its specific efficacy as a potent antitumor agent. *Journal of Health Science*. 54: 654-660. <http://dx.doi.org/10.1248/jhs.54.654>
- Yazdi, H. B., V. Hojati, A. Shiravi , S. Hosseinian , G. Vaezi and M. A. Hadjzadeh, 2019. Liver dysfunction and oxidative stress in streptozotocin-induced diabetic Rrats: Protective role of artemisia turanica. *Journal of Pharmacopuncture*, 22(2): 109–114. <https://doi.org/10.3831/KPI.2019.22.014>.
- Yu, S.G., C. Zhang, X. Xu, J. Sun, L. Zhang and P. Yu, 2015. Ursolic acid derivative ameliorates streptozotocin-induced diabestic bone deleterious effects in mice. *International Journal of Clinical and Experimental Pathology*, 84:3681-90. <http://www.ncbi.nlm.nih.gov/pmc/articles/pmc4466936/>